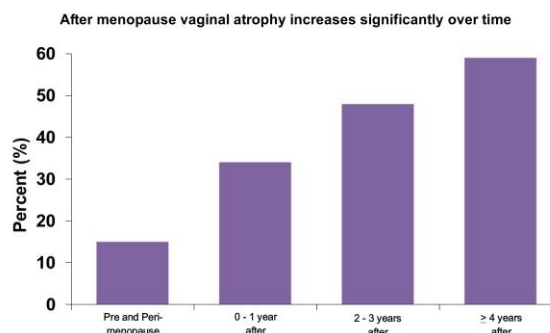


# Treatment of Vaginal Atrophy using a Fractional Microablative CO<sub>2</sub> Vaginal Laser

*A review of the literature, by Bryan S. Jick, MD, FACOG  
Fair Oaks Women's Health, Pasadena, California*

Vaginal Atrophy (VA) refers to the changes seen in the vaginal mucosa and the vagina itself due to loss of estrogen after menopause and in other hypoestrogenic states such as in breast cancer patients on Tamoxifen or even in breastfeeding postpartum women. The symptoms of vaginal dryness, vaginal burning, dysuria, urgency, nocturia and dyspareunia can be severe. Of particular concern is dyspareunia as this can have drastic effects on the patient's marital relationship and a serious negative effect on her overall quality of life.

Hot flashes and night sweats are the early symptoms of menopause. The symptoms of vaginal atrophy take longer to develop, but within 4-5 years after menopause in patients who are not exposed to estrogen, or usually by age 55, almost 50% of women will experience these symptoms to some degree.



Other changes include the progressive loss of elasticity and of the rugal folds of the vaginal lining which becomes thinner and may show petechiae. Sebaceous glands reduce the production of secretions and therefore, during sexual activity, lubrication is decreased and delayed. Histologically, there is severe thinning of the stratified squamous mucosa that lines the vagina, and loss of glycogen and decreased circulation in the lamina propria (the submucosa).

For years treatment options were vaginal lubricants and systemic or vaginal estrogen. But millions of women either cannot use estrogen at all, refuse to use it due to concerns about cancer and other adverse reactions (such as pulmonary embolism, myocardial infarction or stroke), or have tried these other therapies without success.

Osphena, a new oral SERM (selective estrogen receptor modulator) has recently been approved. Although heavily marketed for dyspareunia, the drug is just marginally effective and can cost up to \$2,500 per year.

There is now a new treatment for VA, involving the use of a vaginal laser<sup>1</sup>. For years, fractional CO<sub>2</sub> laser has been shown to provide safe and effective tissue remodelling properties in many body regions, such as the skin of the face, neck and chest. The CO<sub>2</sub> laser wavelength is 10,600 nm, in the infrared range, highly absorbed by water.

A fractional CO<sub>2</sub> laser pulse generates microscopic laser "spots" in the treatment area (called a punctiform pattern). Each "spot" is a micro milli-meter tissue burn with a depth less than that of the surface epithelium. Additionally, there is a small thermal spread to the sub-epithelial layer, which is the intended target of the laser energy.

By using a precisely tuned and programmed optomechanical scanner, a one square cm. area of tissue might have 50 laser spots burned into it. The specific fractioning map is important because there is healthy tissue surrounding each single spot area which allows for rapid and complete epithelial repair (the healing of vaginal epithelium originates in the sub-epithelial layer, which contains fibroblasts, connective tissues and blood vessels).

In cases of vaginal atrophy, water is less present in the dry surface epithelium of the vaginal wall and is more present in the underlying connective tissue. Therefore, minimal damage occurs to the actual vaginal epithelium while more thermal energy is absorbed by the sub-epithelial layer.



**Laser Vaginal Probe**

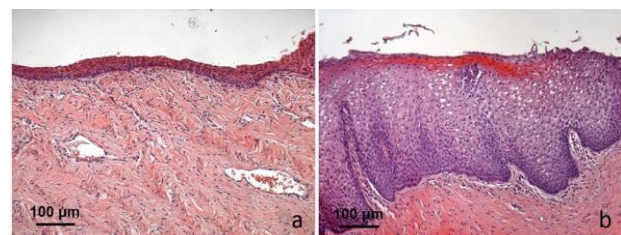
In a 2011 study<sup>i</sup>, patients were treated with a vaginal fractional CO<sub>2</sub> laser a few weeks prior to planned vaginal reconstructive surgery. A special vaginal laser probe with an angled mirror was designed expressly for this procedure. Histological studies were done on the removed vaginal tissues, showing regeneration of the vaginal mucosa and submucosa, increased collagen and elastin, increased microvessel circulation, thickening of the submucosa and mucosa, and restoration of glycogen.

In 2014<sup>ii</sup>, a pilot study designed to assess the efficacy and feasibility of fractional CO<sub>2</sub> laser in the treatment of VA in postmenopausal women was published. The pilot study involved 50 postmenopausal women. They all had documented symptoms of vaginal atrophy (VA) and were more than one year postmenopause and not using estrogen. Their average age was 60. The treatment protocol involved 3 vaginal laser procedures spaced 4 weeks apart with a 12 week follow-up (4 weeks after the third procedure). Data was collected at baseline, prior to each laser procedure, and at the 12 week follow-up, regarding symptom severity, quality of life impact and cytologic vaginal atrophy assessment.

The results were excellent. One hundred percent of the women stated that the treatment was easy, and treatment time was under 5 minutes per procedure. Vaginal atrophy assessment showed statistically significant improvements after each treatment. Quality of life significantly improved ( $p < 0.001$ ) on two different rating scales. 84% of the patients were satisfied or very satisfied with the results overall.

A histologic analysis was published recently<sup>iii</sup>, using vaginal biopsies obtained from 5 of the women in the above pilot study. A 1 mm vaginal wall punch biopsy was obtained prior to any laser treatment and then additional biopsies were obtained 1 month and 2 months after the final laser treatment. Light and electron microscopy were performed on all biopsy specimens.

According to the author, Dr. Nicola Zerbinati, “our microscopic and ultrastructural findings demonstrate the recovery of the whole structures supporting a full functionality in the epithelial and connective tissue compartments since the restored structure represents a restored physiological condition. In the sections treated with the PAS method, a large amount of glycogen was present in the cytoplasm of the intermediate layer cells and the numerous exfoliating cells of the superficial layer. Inside the papillae, elongated blood capillaries were also easily identifiable.



**Atrophic Mucosa**

**2 months later**

Dr. Zerbinati concludes in his paper: “Our results strongly support the hypothesis that a new production of collagen and ground substance components within the connective tissue and glycogen and acidic mucins within the epithelium can rebalance and restore vaginal mucosa from atrophy induced by the absence of ovarian estrogens, resulting in a highly significant improvement in clinical symptoms.”

Dr. Salvatore later published a follow-up study “Sexual function after fractional microablative CO<sub>2</sub> laser in women with vulvovaginal atrophy” conducted in Milan, Italy<sup>iv</sup>. This involved 77 postmenopausal women (average age 60) treated in 2013 and 2014. Three vaginal laser procedures were performed 4 weeks apart and there was a final follow-up 4 weeks after the third procedure (12 week follow-up). Data was collected on vaginal symptom severity, and specific questionnaires designed to assess sexual dissatisfaction (using a scale of 1-10) were also used. Results were obtained at base-line, before each laser treatment and at the 12 week follow-up (4 weeks after the third treatment).

At baseline, 75% of the women were sexually active and 25% were not. By the end of the study, 96% of the women were sexually active. After the first laser procedure 85% of the non sexually active women were able to resume sexual activity.

When compared with baseline (4.3 +/- 1.3), the overall satisfaction with sexual life was significantly higher at the 12-week follow-up (7.7 +/- 1.6; p<0.001) in sexually active women.

This prospective study demonstrated that fractional microablative CO<sub>2</sub> laser is associated with a significant improvement in sexual function and overall satisfaction with sexual life in postmenopausal women complaining of VA symptoms.

“After one cycle of laser treatment, 85% of sexually inactive women, presumably as a consequence of VA, resumed an active sexual life. Such a positive effect was likely related to both restoration of genital tissues and alleviation of urogenital symptoms. Indeed, our current data confirmed the efficacy of fractional microablative CO<sub>2</sub> laser treatment in improving VA symptoms and quality of life at the 12-week follow-up; these results are consistent with the ones of our previous pilot study<sup>ii</sup> showing also a significant improvement in the vaginal health index.”

In conclusion, according to Dr. Salvatore, “...vaginal non-hormonal treatments are an integral part of an overall strategy to promote successful urogenital aging, especially in those women avoiding local estrogens for several reasons, i.e. fears, side-effects, convenience, poor compliance, lack of efficacy and contraindications.”

The results of the above studies were so positive that Cynosure, Inc., one of the largest medical laser companies in the world (NASDAQ: CYNO), decided to bring to the U.S. market the MonaLisa Touch laser using the exact same SmartXide2 Fractional CO<sub>2</sub> laser utilized in the Italian laser studies, manufactured by Deka Lasers in Florence, Italy. Cynosure obtained FDA marketing approval in September, 2014.

In the U.S., a pilot study was conducted at Stanford and at Christ Hospital in Cincinnati<sup>v</sup>. The lead investigator was Dr. Mickey Karram, a world-renowned urogynecologist who is the Director of the Fellowship program on Female Pelvic Medicine and Reconstructive Surgery at the Christ Hospital, Cincinnati, OH.

The results of this trial of 30 postmenopausal women and breast cancer survivors were as follows:

- Overwhelmingly positive and immediate results
- Highly statistically significant improvement in symptoms (including dryness, pain, itching, painful urination and painful intercourse) after the first treatment
- No reported side effects or adverse reactions
- Escalation of progress with each subsequent treatment

## Conclusions

Multiple published peer-reviewed studies and scientific presentations support the following conclusions:

- 100% of the women in one study found the treatment to be quite easy, with a single laser treatment lasting 5 minutes or less
- Sexually inactive post-menopausal women were able to resume their sex life after a single laser treatment with the CO2 vaginal laser
- Fractional CO2 vaginal laser treatment is a safe and effective treatment for vaginal atrophy
- There is a new non-hormonal option for the treatment of vaginal dryness, vaginal burning, and painful intercourse due to loss of estrogen after menopause or as seen in breast cancer survivors

Fair Oaks Women's Health has obtained this exciting new laser and is currently successfully treating these patients. We call our procedure the Valayza™ Procedure. For more information, see our web site ([www.fowh.com/Valayza](http://www.fowh.com/Valayza)) or call our Valayza™ hotline at 844-VALAYZA.



## References

- 
- <sup>i</sup> Salvatore S, Digesu G, Siesto G, et al. Vaginal collagen remodelling after fractional carbon dioxide laser surgery [abstract 233]. Presented at Annual Meeting of the International Continence Society, Glasgow, United Kingdom, August – September 2011
  - <sup>ii</sup> S. Salvatore et al. A 12-week treatment with fractional CO2 laser for vulvovaginal atrophy: a pilot study. *Climacteric* Aug 2014, Vol. 17, No. 4: 363–369.
  - <sup>iii</sup> N. Zerbinati et al. Microscopic and ultrastructural modifications of postmenopausal atrophic vaginal mucosa after fractional carbon dioxide laser treatment. *Lasers Med Sci* (2015) 30:429–436.
  - <sup>iv</sup> S. Salvatore et al. Sexual function after fractional microablative CO2 laser in women with vulvovaginal atrophy. *Climacteric* 2014 Oct 21:1-21.
  - <sup>v</sup> Karram M and Sokol E. A new and novel therapy for vulvovaginal atrophy: results of the first U.S. trial. Presented at 2014 Pelvic Anatomy and Gynecologic Surgery Symposium (PAGS), Las Vegas, NV.